Figures

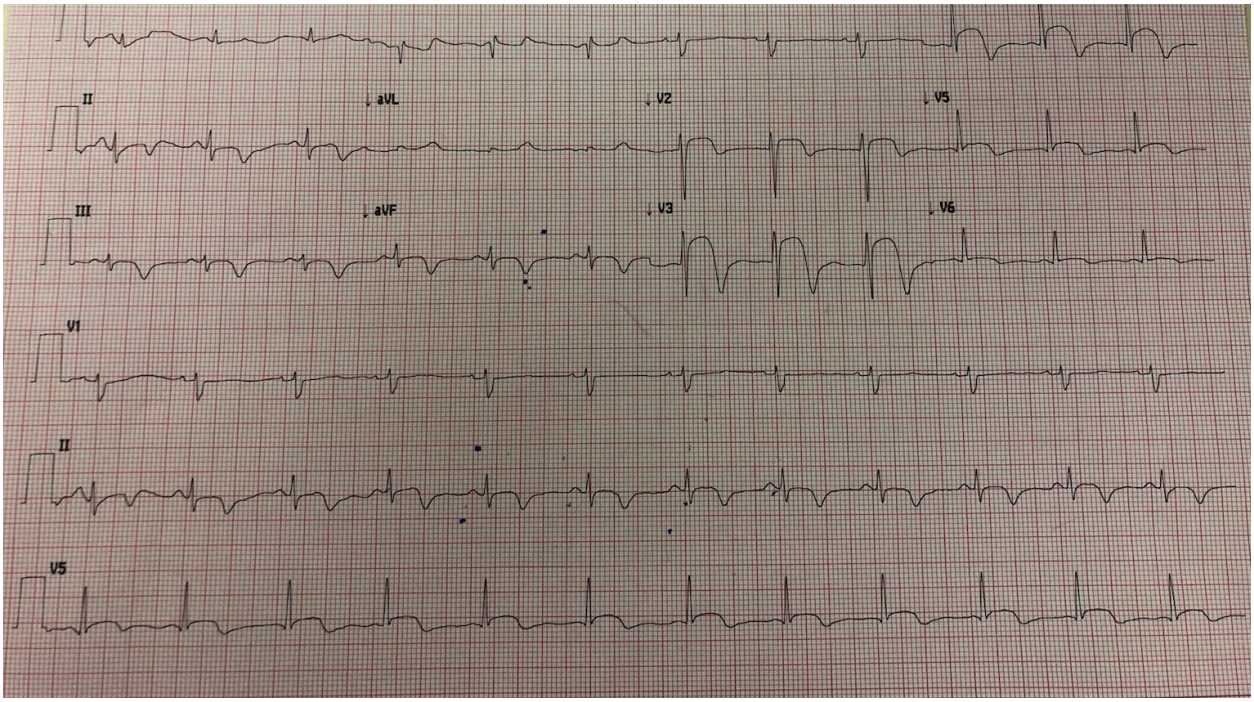

Figure 1. ECG on presentation to outside hospital

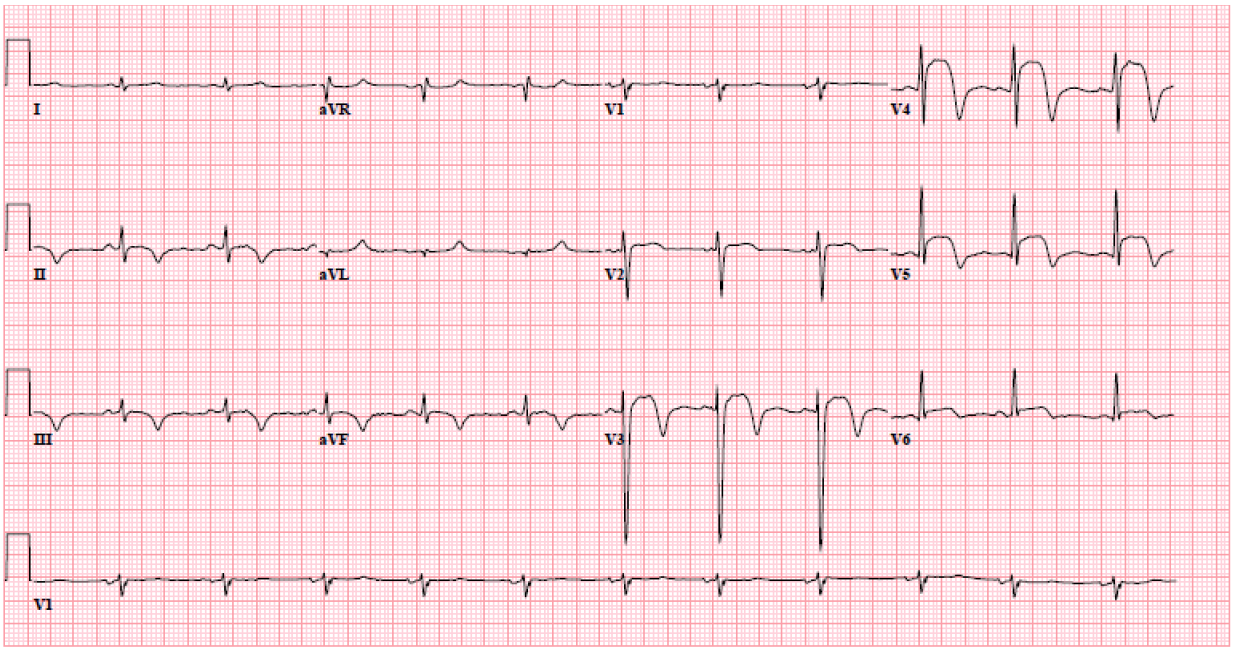

Figure 2. ECG on presentation to our institution

A.

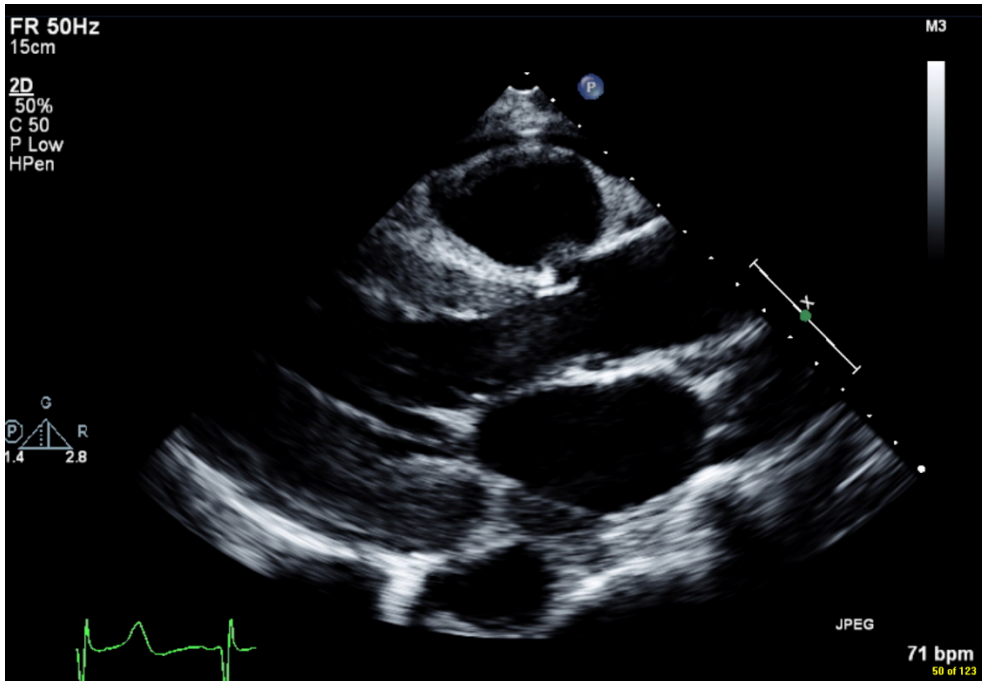

B.

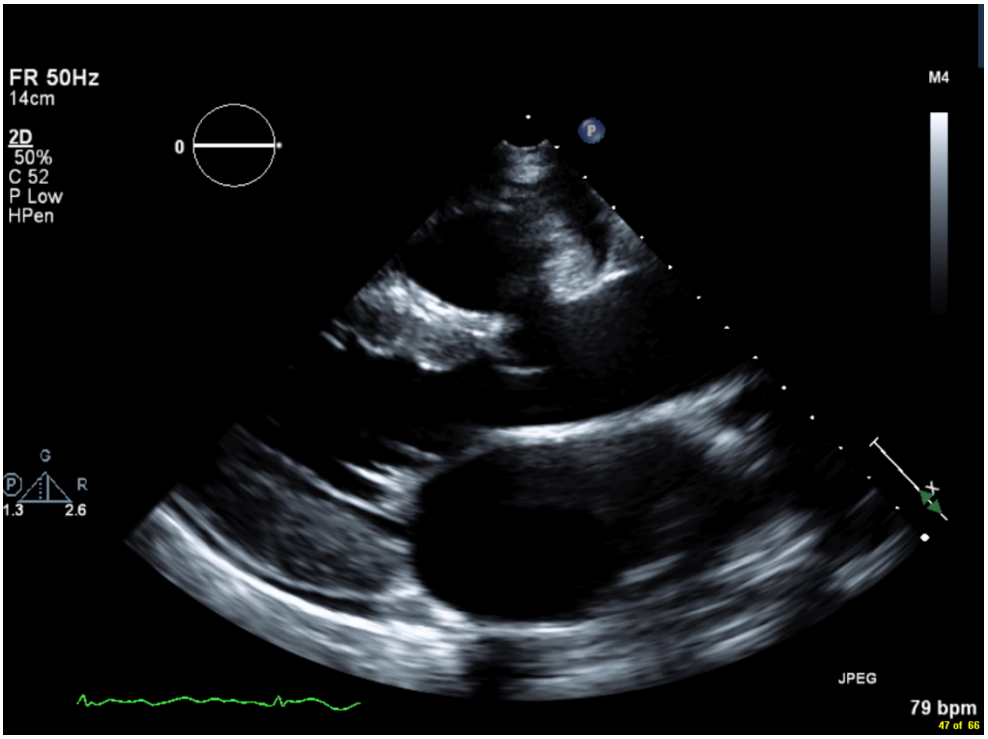

Figure 3. Parasternal long axis view of transthoracic echocardiogram, at presentation (A) and after 2 cycles of chemotherapy (B)

A.

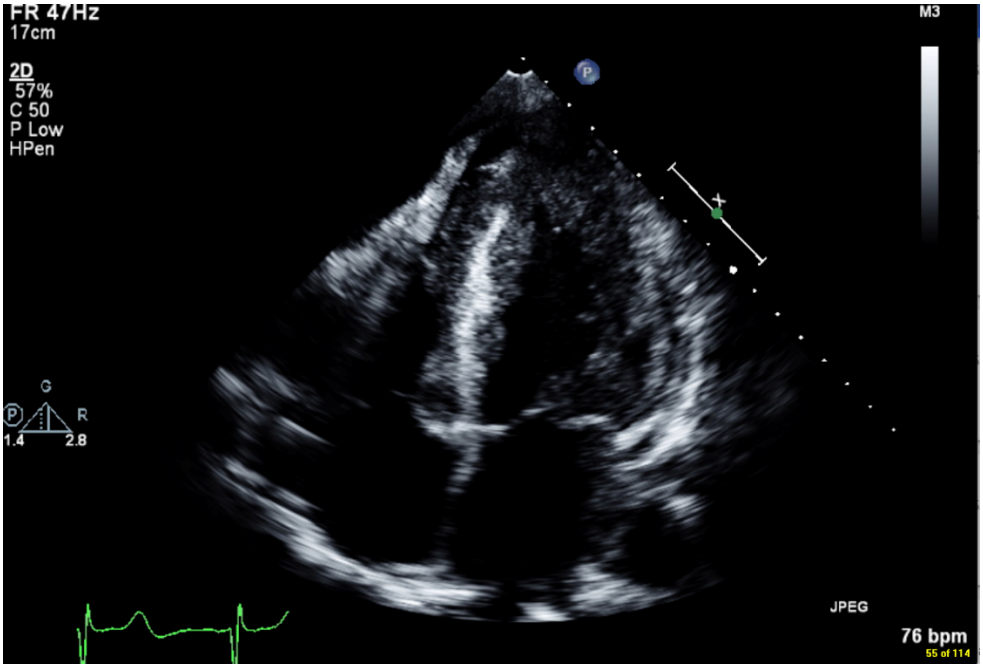

B.

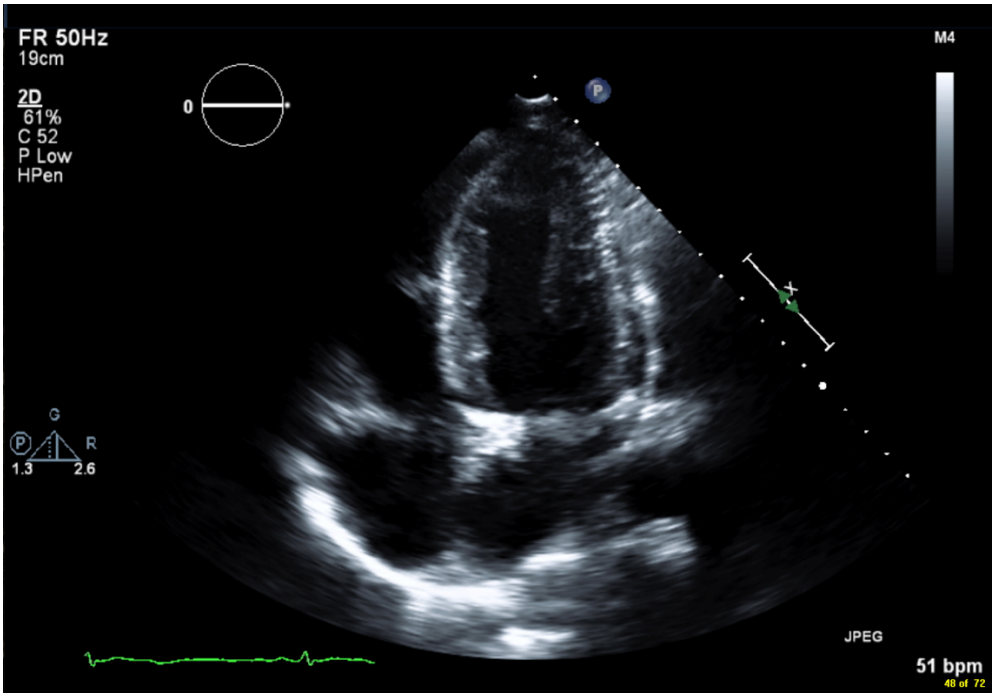

Figure 4. Apical four chamber view of transthoracic echocardiogram at presentation (A) and after 2 cycles of chemotherapy (B)

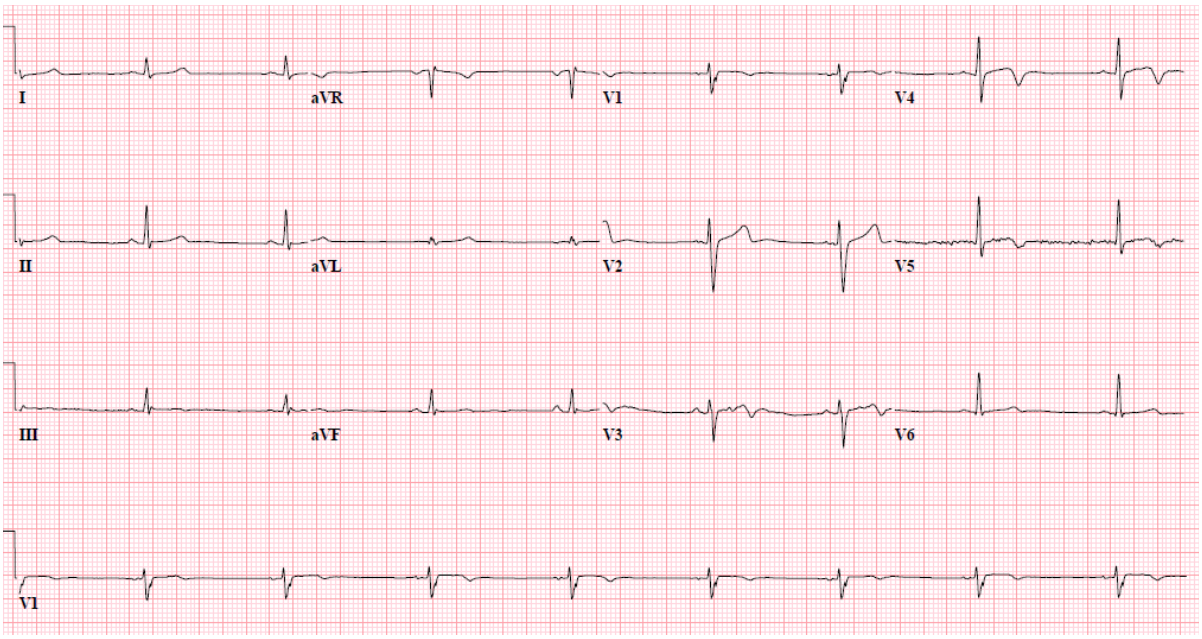

Figure 5. ECG after 3 cycles of chemotherapy