It's All In The Tissue: A Rare Case of Acute Cardiogenic Shock

A 53-year-old female with a history of hypothyroidism presented with a 2-week history of dyspnea and abdominal pain. Exam revealed a heart rate of 120 bpm, blood pressure of 87/69 mmHg, elevated JVP, and a 3/6 holosystolic murmur. EKG showed 2 mm ST-segment elevations in V1-V3 and ST-segment depressions in lateral limb leads. Labs showed transaminitis, elevated troponin-T, lactic acid and leukocytosis. An echocardiogram revealed severely reduced global biventricular dysfunction with a normal chamber size. Differential included acute coronary syndrome and myocarditis, with unknown subtype.

Coronary angiogram revealed normal coronaries, while right heart catheterization found elevated biventricular pressures/low flow (RA 19 mmHg, RV 33/15 mmHg, PAP 32/19/25 mmHg, PCWP 25 mmHg, Fick CI 1.5 L/min/m^2). Endomyocardial biopsy was performed to assess acute cardiogenic shock. Intra-aortic balloon pump was placed for stabilization, but she developed ventricular arrhythmias and urgently underwent implantation of CentriMag biventricular assist devices. The biopsy revealed a diffuse lymphocytic infiltrate and multinucleated giant cells without granulomas consistent with giant cell myocarditis (GCM) (Fig 1). A combination of high-dose prednisone, Tacrolimus and IVIG was initiated. The patients' condition improved and 12 days following BiVAD implantation the patient had "turn-down" study of the BiVADs (simultaneous echocardiographic and hemodynamics step wise reduction in speed which showed evidence of myocardial recovery). The devices were explanted and the patient was discharged on oral medical therapy plus immunosuppression.
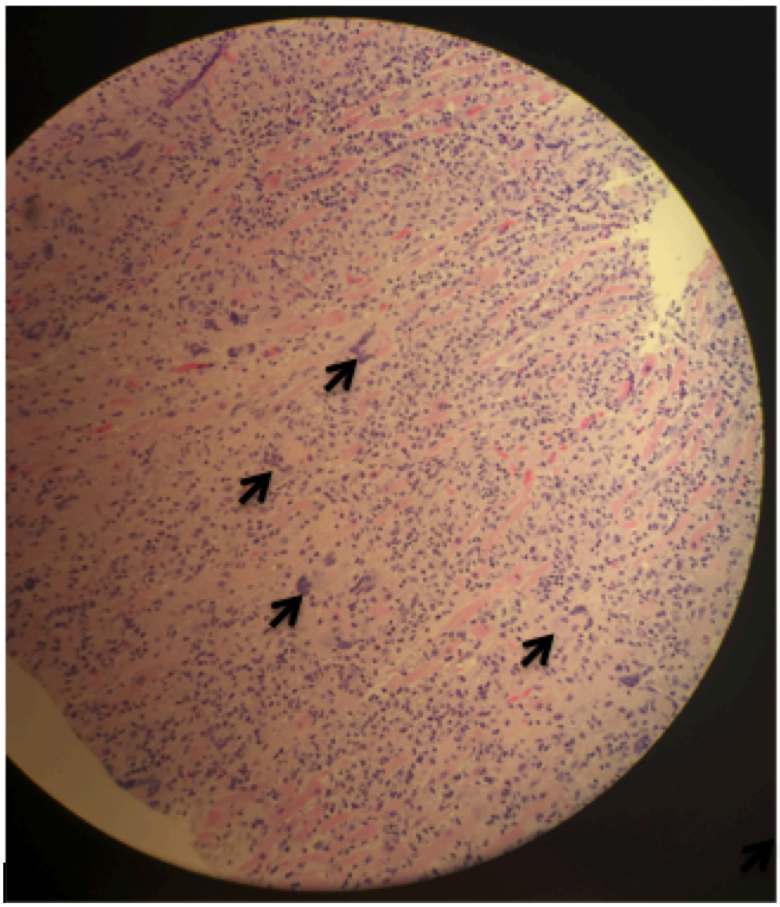
The case discusses the (1) indication for early endomyocardial biopsy in setting of cardiogenic shock with unknown etiology (2) medical therapy for GCM include steroids/Tacrolimus (3) acute mechanical support in the setting of myocarditis complicated by cardiogenic shock and (4) turn down study to assess myocardial recovery.