A Life-Threatening Infection in the CICU: When a Broken Heart Gives You a Rash

A 30-year-old female was admitted for severe nausea, vomiting, and altered mental status. The patient had a past medical history of treatment-naïve Hepatitis C and remote intravenous drug abuse that was complicated by methicillin-resistant *Staphylococcus aureus* tricuspid valve endocarditis. She underwent a bioprosthetic tricuspid valve replacement sixteen months previously however suffered a heroin relapse six months later that was complicated by recurrent endocarditis; surgical valve replacement was declined and she was medically managed with six weeks of intravenous gentamycin, cefazolin, and rifampin. She was doing well until this presentation and taking no medications.

Her vital signs upon presentation were significant for fever of 40.5 °C, blood pressure 70/30 mmHg, heart rate 134 beats per minute, and respiratory rate of 34 breaths per minute with appropriate oxygen saturation. Physical exam was remarkable for jugular venous distention of 10 cm and grade II/VI holosystolic and diastolic murmurs at the left lower sternal border. Skin had a livedo reticularis appearance with numerous tattoos and no rashes. Electrocardiogram revealed sinus tachycardia with rightward axis deviation and right atrial enlargement. Admission labs were significant for white blood cell count of 23.4×10^9/L ($3.7–11.0 \times 10^9$/L), platelet count of 37,000/µL ($150–400 \times 10^3$/µL), lactic acidosis of 6.9 mmol/L (0.5–2.2 mmol/L), PT INR of 1.8 (0.9–1.3), D-dimer > 35,200 ng/mL (<500 ng/mL), and fibrinogen 234 mg/dL (200–400 mg/dL). Blood cultures were collected, and the patient was started on empiric antibiotic therapy with vancomycin and piperacillin-tazobactam due to concern for septic shock secondary to infective endocarditis.

Admission blood cultures grew methicillin-resistant *S. aureus* and remained positive on repeated cultures for the next sixteen days; cultures ultimately cleared following transition from vancomycin to ceftaroline. Both transthoracic and transesophageal echocardiograms demonstrated severely thickened tricuspid bioprosthetic valve leaflets with severe stenosis and a large mobile echodensity consistent with a vegetation. CT of the brain, chest, abdomen, and pelvis demonstrated subpleural nodules concerning for embolic phenomena.

Initially, she was profoundly hypotensive requiring aggressive volume resuscitation and maximal doses of three vasopressors. She was additionally supported with continuous veno-venous hemodialysis due to acute renal failure. With these measures, she became hemodynamically stable by hospital day three. However, her skin lesions did not resolve and, by hospital day five, had significantly progressed to include 1) blue discoloration of her distal nose and ears, 2) large purpuric plaques on arms and legs, most severe distally and of all digits, and 3) scattered bullae distally within purpuric plaques with large areas of grey discoloration suggestive of impending necrosis (Figure 1). The differential at this juncture included vasopressor-induced skin necrosis, vasculitis, cryglobulinemia, viral-induced, or DIC-mediated purpura fulminans. Further work-up was performed as follows: C3 86 mg/dL (86–166 mg/dL), C4 14 mg/dL (13–46 mg/dL), negative cryoglobulins, serum levamisole, lupus anticoagulant, and negative serologic testing for active Hepatitis B, human immunodeficiency virus, and anti-neutrophilic cytoplasmic antibodies. Function of Protein C was 45% (76–147%), Protein S 31% (59–131%), and antithrombin 54% (84–138%). These constellation of findings were consistent with purpura fulminans with secondary bullae formation. On hospital day seven, intravenous human protein C concentrate (Ceprotin) was initiated with 100 units/kg bolus followed by 50 units/kg infusion every six hours. With this, her lesions rapidly and significantly improved (Figure 2). She was taken to the cardiac operating room on hospital day nineteen with operative findings notable for an obstructive vegetation involving all three tricuspid valve leaflets, an abscess cavity around the annulus, and vegetations extending into right ventricle and the subvalvular space. She underwent removal and debridement of the infected bioprosthetic valve (Figure 3a) followed by bioprosthetic valve replacement. Movat staining showed a pericardial tissue valve with marked acute inflammation and organizing thrombus (Figure 3b). Gomori methenamine silver stain showed bacterial cocci which on gram stain revealed gram positive cocci in clusters.

Post-operatively she did well, though remained dialysis dependent. Dry gangrene of her left foot and several right toes persisted. For this, Vascular Surgery is to see the patient in clinic once wounds have fully demarcated with plans for consideration of amputation. She was ultimately discharged to a skilled nursing facility after completion of ceftaroline for six weeks for further rehabilitation given prolonged hospital stay.

DISCUSSION

Sepsis-associated purpura fulminans has a high mortality rate and includes four primary features: large, purpuric skin lesions, fever, hypotension, and disseminated intravascular coagulation. Meningococcemia is, by far, the infection most commonly attributed to purpura fulminans, followed by Streptococcal infection.[1] However, despite thirty-five million estimated hospital discharges annually in the United States related to *S. aureus* bacteremia[2,3], there is a scant association between this organism and purpura fulminans.[4-8] In the current opioid epidemic, this presentation may become more commonly encountered in clinical medicine.

Staphylococcus aureus causes disease by invasion and elaboration of exotoxins. Two toxins in particular, TSST-1 and staphylococcal enterotoxin serotype B or C, are capable of functioning as superantigens by non-specifically attaching outside the antigen-binding cleft to class II major histocompatibility complex molecules on antigen-presenting cells.[9] These antigens trigger clonal activation of T cells which triggers a massive release of cytokines by both macrophages (IL-1β and TNF-α) and T cells (IL-2, IFN-γ, and TNF-β) manifesting as toxic shock syndrome.[10]

Protein C becomes activated in the microcirculation by the binding of thrombin to the endothelial surface glycoprotein, thrombomodulin.[11] Activated protein C functions to inactivate coagulation factors Va and VIIa and promotes fibrinolysis both by inhibition of plasminogen activator inhibitor and reduction of the thrombin activatable fibrinolysis inhibitor. In addition, protein C has strong anti-inflammatory properties and may potentially decrease endothelial cell apoptosis in response to inflammatory cytokines.[12]

During the acute inflammatory response, an acquired deficiency of endogenous anticoagulants, including protein C, protein S, and antithrombin, develops.[13] Protein C in particular is disparately reduced during this process. This may in part be explained by a reduction in vessel wall expression of thrombomodulin and the endothelial cell protein C receptor. A rapid and prolonged depletion of protein C occurs in septic shock, presumably due to increased consumption, degradation, or decreased hepatic synthesis, and contributes to sepsis-induced coagulopathy.[14] As a result, there is widespread microvascular thrombosis with tissue toxicity and injury from an overall procoagulant effect and the production of proinflammatory cytokines. There is a strong correlation between the severity of the activated protein C deficiency and the extent of thrombotic skin lesions and adverse clinical outcomes.[15] In experimental models, use of activated protein C has been shown to decrease hypercoagulability, block tumor necrosis factor production, inhibit neutrophil attachment to selectins, and improve outcomes with meningococcal shock.[13,16]

Although the therapeutic use of activated protein C in severe septic states has been entertained since 1990 with several large randomized controlled trials investigating its efficacy[17,18], limited data exists regarding its use in patients with purpura fulminans with most published experience in the form of isolated case reports or retrospective case series.[8,19-21] In a randomized study investigating the use of protein C concentrate in children with severe meningococcal sepsis and purpura fulminans, treatment was noted to be safe and led to dose-dependent increases of plasma activated protein C levels and resolution of coagulation imbalances.[22] Although there was no significant observed mortality benefit, this study did demonstrate that lower baseline levels of activated protein C was a significant predictor for mortality.

CONCLUSIONS

In this case report, we describe the first patient with purpura fulminans secondary to methicillin-resistant *S. aureus* endocarditis who was successfully treated with protein C concentrate and surgical valve replacement. There is minimal association between purpura fulminans and endocarditis with one published case describing purpura fulminans in the setting of confirmed *Streptococcus agalactiae* endocarditis and another describing two patients with methicillin-sensitive *S. aureus*-induced purpura fulminans who presented with meningitis and subsequently developed presumed endocarditis.[6,23] These patients were not treated with protein C concentrate. Future studies with larger number of patients are indicated to determine whether administration of protein C concentrate can reduce mortality or amputation rates, thereby improving outcomes in these critically ill patients.

REFERENCES

1. Levin M, Eley BS, Louis J, Cohen H, Young L, Heyderman RS. Postinfectious purpura fulminans caused by an autoantibody directed against protein S. J Pediatr 1995; 127:355–63.
2. Rubin RJ, Harrington CA, Poon A, Dietrich K, Greene JA, Moiduddin A. The economic impact of *Staphylococcus aureus* infection in New York City hospitals. Emerg Infect Dis 1999; 5:9–17.
3. Wenzel RP, Edmond MB. The impact of hospital-acquired bloodstream infections. Emerg Infect Dis 2001; 7:174–7.
4. Kravitz GR, Dries DJ, Peterson ML, Schlievert PM. Purpura Fulminans Due to Staphylococcus aureus. Clin Infect Dis 2005; 40(7):941-7.
5. Honarpisheh H, Camp R, Lazova R. Staphylococcal Purpura Fulminans: Report of a Case. Am J Dermatopathol 2015; 37(8):643-6.
6. Murray HW, Tuazon CU, Sheagren JN. Staphylococcal septicemia and disseminated intravascular coagulation. Staphylococcus aureus endocarditis minicking meningococcemia. Arch Intern Med 1977; 137(7):844-7.
7. Robboy SJ, Mihm MC, Colman RW, Minna JD. The skin in disseminated intravascular coagulation: prospective analysis of thirty-six cases. Br J Dermatol 1973; 88:221–9.
8. Rintala E, Kauppila M, Seppala OP, et al. Protein C substitution in sepsis-associated purpura fulminans. Crit Care Med 2000; 28:2373–8.
9. Davis JP, Chesney PJ, Wand PJ, et al. Toxic-shock syndrome: epidemiologic features, recurrence, risk factors, and prevention. N Engl J Med 1980; 303:1429–1435.
10. McCormick JK, Yarwood JM, Schlievert PM. Toxic shock syndrome and bacterial superantigens: an update. Annu Rev Microbiol 2001; 55:77–104.
11. Esmon CT. The roles of protein C and thrombomodulin in the regulation of blood coagulation. *J Biol Chem* 1989; 264:4743–4746
12. Esmon CT. The protein C pathway. *Chest* 2003; 124(3 Suppl):26S–32S
13. Faust SN, Levin M, Harrison OB, et al. Dysfunction of endothelial protein C activation in severe meningococcal sepsis. *N Engl J Med* 2001; 345:408–416.
14. Fourrier F, Chopin C, Goudemand J, et al. Septic shock, multiple organ failure, and disseminated intravascular coagulation: Compared patterns of antithrombin III, protein C, and protein S deficiencies. *Chest* 1992; 101:816–823.
15. Fijnvandraat K, Derkx B, Peters M, et al. Coagulation activation and tissue necrosis in meningococcal septic shock: severely reduced protein C levels predict a high mortality. *Thromb Haemost* 1995; 73:15–20.
16. Roback MG, Stack AM, Thompson C, et al: Activated protein C concentrate for the treatment of meningococcal endotoxin shock in rabbits. *Shock* 1998; 9:138–142.
17. Bernard GR, Vincent JL, Laterre PF, LaRosa SP, Dhainaut JF, Lopez-Rodriguez A, Steingrub JS, Garber GE, Helterbrand JD, Ely EW, Fisher CJ, et al. Efficacy and safety of recombinant human activated protein C for severe sepsis. N Engl J Med 2001; 344(10):699-709.

18. Ranieri VM, Thompson BT, Barie PS, Dhainaut JF, Douglas IS, Finfer S, Gardlund B, Marshall JC, Rhodes A, Artigas A, Paven D, Tenhunen J, Al-Khalidi HR, Thompson V, Janes J, Macias WL, Vangerow B, Williams MD, et al. Drotrecogin alfa (activated) in adults with septic shock. N Engl J Med 2012; 366(22):2055-64.
19. Gerson WT, Dickerman JD, Bovill EG, et al. Severe acquired protein C deficiency in purpura fulminans associated with disseminated intravascular coagulation: Treatment with protein C concentrate. *Pediatrics* 1993; 91: 418–422.
20. White B, Livingstone W, Murphy C, et al: An open-label study of the role of adjuvant hemostatic support with protein C replacement therapy in purpura fulminans-associated meningococcemia. *Blood* 2000; 96:3719–3724.
21. Smith OP, White B, Vaughan D, et al. Use of protein-C concentrate, heparin, and haemodiafiltration in meningococcus-induced purpura fulminans. *Lancet* 1997; 350:1590–1593.
22. De Kleijn ED, de Groot R, Hack CE, Mulder PG, Engl W, Mortiz B, Joosten KF, Hazelzet JA. Activation of protein C following infusion of protein C concentrate in children with severe meningococcal sepsis and purpura fulminans: a randomized, double-blinded, placebo-controlled, dose-finding study. Crit Care Med 2003;31(6):1839-47.
23. Hall WH. Purpura fulminans with group B Beta-hemolytic streptococcal endocarditis. Arch Intern Med 1965;116(4):594-7.

FIGURES

Figure 1. Purpuric plaques noted on face and distal extremities with evidence of impending necrosis, diagnostic of purpura fulminans with secondary bullae formation.

Figure 2. Skin lesions (A) before and (B) after receipt of protein C concentrate.

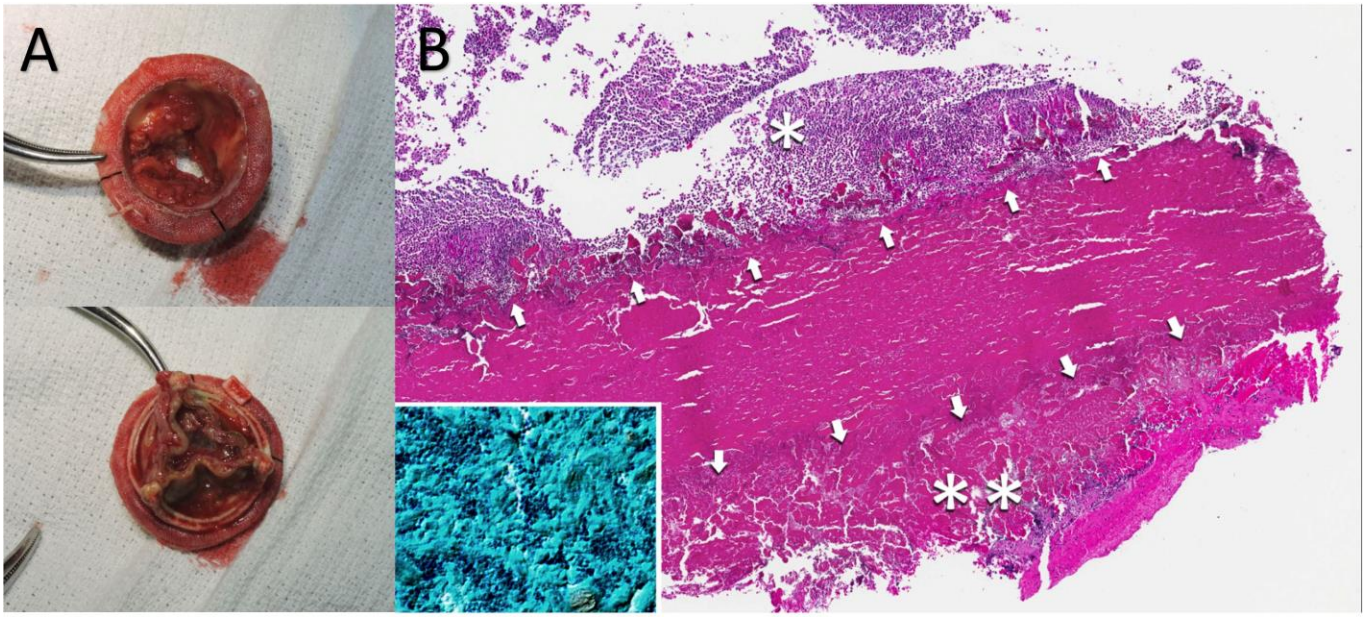

Figure 3. (A) Atrial and ventricular aspects of the infected bioprosthetic tricuspid valve. (B) Histologic examination shows a bovine pericardial tissue valve delineated by the arrows with acute inflammatory exudate (asterisk) and fibrinous vegetation (double asterisk). The diagnosis of bacterial endocarditis is confirmed by demonstrating the presence of bacterial cocci on the Gomori methenamine silver stain (inset).